

Non-catastrophic Deep Cerebral Vein Thrombosis in COVID-19: Case report

Case Report

Hernán Mauricio Patiño-Rodríguez¹, Angie Viviana Parra-Guacaneme¹, Claudia Marcela Moreno-Rodríguez¹, Cesar Daniel Torres-López¹ and Karen Lorena Horta-Garavito¹

¹ *Department of Neurology, University Foundation of Health Sciences - Hospital Universitario Infantil de San José, Bogotá D.C., Colombia*

Reception date of the manuscript: 14/October/2020

Acceptance date of the manuscript: 05/January/2021

Publication date: 07/January/2021

DOI: 10.5281/zenodo.4424638

Abstract— Non-catastrophic Deep Cerebral Vein Thrombosis in COVID-19: Case Report

Introduction. SARS-CoV-2 infection responsible for COVID-19, has demonstrated neurotropic and neuroinvasive potential, displaying several neurological manifestations ranging from mild to severe complications, the latter related to a prothrombotic state, giving place to stroke and less often cerebral venous thrombosis. The physiopathology of these events is currently elucidated from various mechanisms including thrombo-inflammation, endotheliopathy, and stasis in critically ill patients. **Case Report.** We present the case of a 48-year-old woman that develops cerebral venous thrombosis in the context of a COVID-19 infection. **Discussion.** Cerebral venous thrombosis is a possible complication of COVID-19 in any stage, even in patients with a non-severe course of the disease; the mechanism involved is probably related to microcirculatory dysfunction enhanced by prothrombotic comorbid conditions. **Ictus 2021;2(1):e07012102010**

Keywords—COVID-19, Headache, Intracranial Sinus Thromboses, Stroke, SARS-CoV-2.

Resumen— Trombosis Venosa Cerebral Profunda en Paciente con COVID-19: Reporte de Caso

Introducción. La infección por SARS-CoV-2, responsable de COVID-19 ha demostrado potencial neurotrópico y neuroinvasor, exhibiendo múltiples manifestaciones neurológicas que varían de leves a severas, estas últimas relacionadas a un estado protrombótico que da lugar a la aparición de accidentes cerebrovasculares y con menor frecuencia trombosis venosa cerebral. La fisiopatología de estos eventos actualmente se relaciona con varios mecanismos incluyendo trombo-inflamación, endotelopatía y estasis sanguínea en pacientes críticos. **Caso Clínico.** Presentamos el caso de una mujer de 48 años que desarrolla una trombosis venosa cerebral en el contexto de una infección por COVID-19. **Discusión.** La trombosis venosa cerebral es una complicación posible de COVID-19 en cualquier etapa, incluso en pacientes con curso no severo de la enfermedad, en estas condiciones probablemente asociado a disfunción microvascular potenciada por condiciones comorbidas protrombóticas. **Ictus 2021;2(1):e07012102010**

Palabras clave—COVID-19, Cefalea, Trombosis Venosa Cerebral, Ictus, SARS-CoV-2.

INTRODUCTION

SARS-CoV-2 infection has become pandemic, is well known to cause substantial pulmonary disease, including pneumonia and acute respiratory distress syndrome (ARDS), many extrapulmonary manifestations of COVID-19 have been identified due to the wide expression of ACE2 entry receptor in multiple extrapulmonary tissues, causing thrombotic complications, gastrointestinal symptoms, kidney and myocardial dysfunction.¹

Neurological events have been documented with a frequency up to 36.4% ranging from mild symptoms as taste and smell impairment, dizziness and headache, to severe with impaired consciousness, neuromuscular injury and acute cerebrovascular diseases,² the latter more likely to occur in patients with higher severity of illness.

CASE REPORT

A 48-year-old woman with past medical history remarkable for affective bipolar disorder and chronic anemia due, presented with 5 days of increasing severity headache and dizziness, 24 hours before hospital admission showed diminished language production and interaction, progressing to altered mental status, the next day is found with no language emission and right-sided weakness. Review of systems accounts for dry cough, dyspnea, and fever 10 days earlier, also present in 4 of her family members, some of them with diarrhea.

In the emergency room is found with TA: 113/69mmHg, T: 36°C, HR: 77bpm, oxygen saturation of 94%, normal general physical examination, neurological exam positive for global aphasia, right-sided hypoesthesia and hemiparesis.

Non-contrast head CT revealed left deep hemispheric hypodensity and hyperdensity of the ipsilateral deep cerebral venous system detailed in (Figure 1). Due to respiratory symptoms reported on admission, a non-contrast chest CT was performed at the same time, found findings compatible with viral pneumonia (Figure 2). These results lead to the diagnostic impression of deep cerebral venous thrombosis, later established by MRI venous angiogram (Figure 3). COVID-19 infection was confirmed by a positive nasopharyngeal swab with an RT-PCR for SARS-CoV-2. Laboratory findings revealed the presence of iron deficiency anaemia and sub-clinic hyperthyroidism, tests for thrombophilia were negative, laboratory findings listed in Table 1. predicted a non-severe clinical course.

The patient was treated with low molecular weight heparin (LMWH), neurological improvement was observed from day 5, the NIHSS score improved from 19 to 9 mainly due to

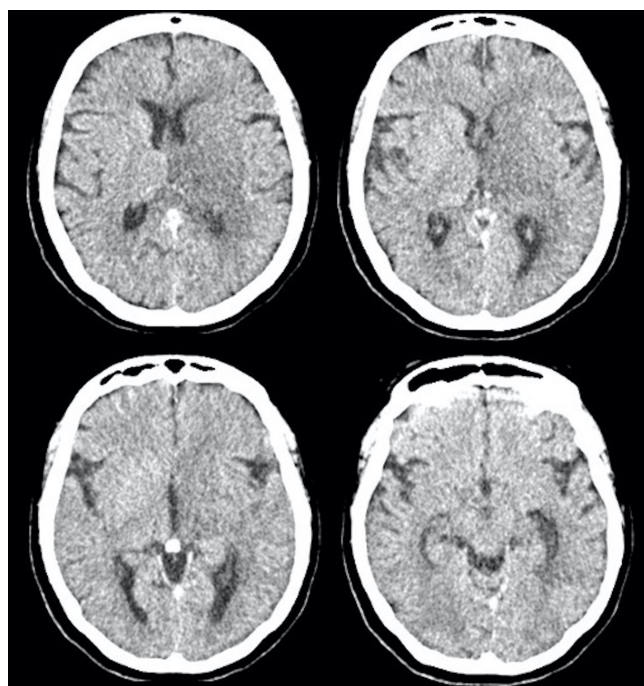


Figure 1: Non-contrast head CT shows left deep hemispheric hypodensity involving the basal ganglia, thalamus, internal capsule and the deep white matter. Hyperdensity of the proximal internal cerebral veins and vein of Galen, without acute signs of hemorrhagic transformation.

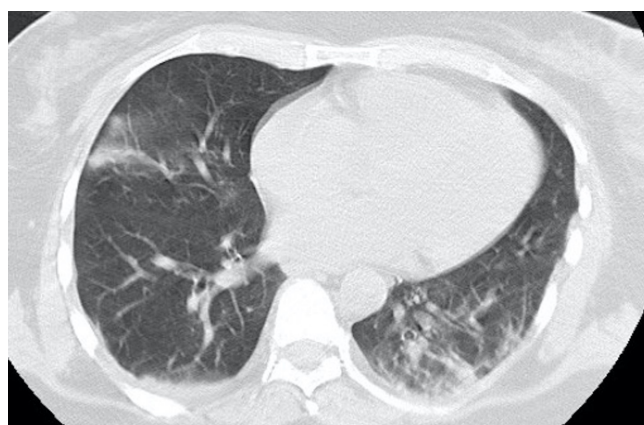

Figure 2: Non contrast chest CT showing subpleural – Multifocal bilateral ground-glass opacities and consolidation of the basal and posterior aspect of the left lung, suggestive of viral pneumonia.

language and mild strength recovery, 2 weeks later she was considered for discharge.

DISCUSSION

We present a case of a young adult with newly diagnosed hyperthyroidism, chronic anaemia and confirmed SARS-CoV2 infection manifesting focal neurological signs due to unilateral deep cerebral vein thrombosis, these conditions are expected to converge in a prothrombotic milieu demonstrating unusual site thrombosis.

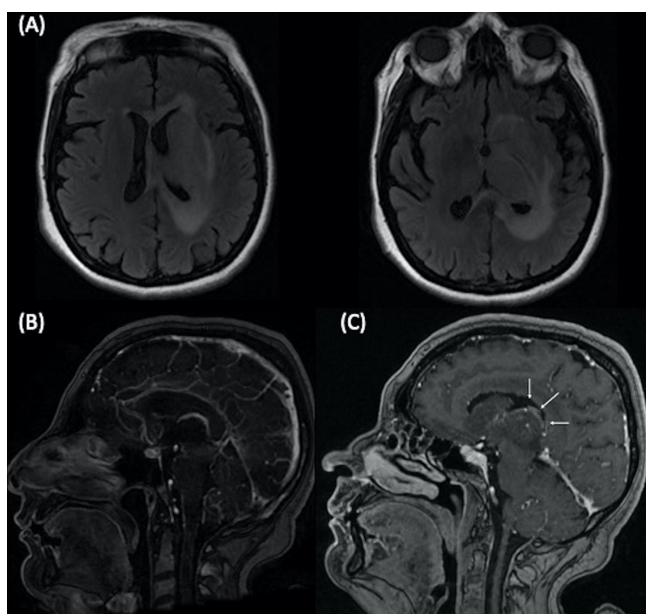


Figure 3: Axial FLAIR showing left vasogenic edema, including the deep grey and white matters (A), Parasagittal postcontrast T1-weighted MR images: normal right deep cerebral vein (B) abnormal opacification of left deep cerebral vein (C).

Laboratory normal range	Laboratory findings
White cell count (5,0-10,1 per 10 mm ³)	7,230
Total neutrophils (1,4-6,5 per 10 mm ³)	6,500
Total lymphocytes (1,2-3,4 per 10 mm ³)	1,230
Hemoglobin level (12-18 g/dL)	7.1
Platelet count (per mm ³)	556,000
Activated partial thromboplastin time (sec)	11.7
Prothrombin time (sec)	22
INR	1.05
D-dimer level (until 198 ng/mL)	220
Fibrinogen level (180-350 mg/dL)	232.9
Ferritin level (9-120) ng/mL	2.9
Troponin I (0.0-0.029)	0.004
Alanin aminotransferase results (0-55 U/L)	46.5
Aspartate aminotransferase results (0-40 U/L)	31.5
DHL (90-190 U/L)	188
CRP (0-3 mg/L)	4.7
Creatinine (0.57-1.25 mg/dL)	0.6
Blood urea nitrogen (4.7-23 g/dL)	21.8
TSH (0.4-4 μUI/mL)	0.256
Free T4 (0.80-1.90 ng/dL)	1.1

TABLE 1: LABORATORY DATA DURING ADMISSION.

Derangement of the coagulation function has been a prominent issue during pandemic, especially in hospitalized patients, severity of disease is directly correlated with increasing values of D-dimer and fibrinogen degradation products compared to healthy people.³ COVID-19-associated coagulopathy (CAC) is a recent term, used to describe the coagulation changes in infected patients, most likely due to a result

of the profound inflammatory response, endotheliopathy and stasis. Early in infection, rising IL-6 levels correlate with elevated fibrinogen and D-dimers, but does not fulfil the usual definition of a clinical coagulopathy were impaired coagulation results in bleeding. Elevated D-dimer at admission associates with higher coagulation-associated complications during hospitalization, risk of requiring mechanical ventilation, intensive care unit (ICU) admission, or death.⁴⁻⁶

Most common thrombotic complications despite the usual critically ill patient thromboprophylaxis include pulmonary embolism, venous thromboembolism, acute myocardial infarction especially among patients with preexisting atherosclerosis;⁷ Li et al. Reported a frequency of 5.9% of acute cerebrovascular disease following COVID-19 in a cohort of 219 patients, 1 patient with severe disease (0.5%) presented cerebral venous sinus thrombosis 14 days after initial symptoms;⁸ these patients show different profile, compared to the historical non-COVID population, developing stroke at a younger age, worse radiographic and clinical outcomes, multiple vessel occlusion, with more extensive clot burden(9). Few other cases of cerebral venous thrombosis have been reported, most of them related to extensive thrombosis and fatal outcome (Table 2).^{8,10-21}

Cerebral venous thrombosis is a potentially catastrophic complication of COVID-19, it remains a diagnostic challenge considering headache and altered mental status might be common symptoms in a moderate course of disease, suspicious must be present in patients with persistent and worsening headache especially in addition to new neurological deficit. Superior sagittal sinus is the most frequently involved (62%) in cerebral venous thrombosis, whereas deep cerebral veins account for less than 11% of all CVT in pre-COVID-19 cohorts;²² This case is significant for an unusual site thrombosis, in a patient with normal levels of fibrinogen and D-dimer related to a non-severe course of COVID-19 and a reduced clot burden; considering the age of the patient thrombophilia studies were performed 1 month after the acute phase of disease ruling out hereditary and autoimmune conditions (Table 3).

These findings relegate the role thrombo-inflammation as the main pathophysiological event, and brings up suspicion of endotheliopathy due to micro-circulatory dysfunction in the ACE2 receptor interaction and vasoactive effects of increased circulating angiotensin II as the major harbinger to thrombosis in addition to other prothrombotic features as iron deficiency anaemia and hyperthyroidism; the former found to be related to impaired absorption due to chronic use of proton-pump inhibitors the 5 previous years.^{5,23}

When therapeutic anticoagulation is considered in admitted patients, LMWH or UFH are preferred instead of oral anticoagulants given their shorter half-lives, ability for parenteral administration, prompt anticoagulation, and anti-inflammatory effects. These are reached by downregulating IL-6 and binding to COVID 19 spike proteins that can improve prognosis in patients with severe disease.^{24,25}

References	Age	Comorbidity	Type of cerebral thrombosis	Time from COVID19	COVID19 severity	Outcome
Li Y, et.al. ⁸	33	Smoker	Not specified	2 weeks	Severe	Survival
Hughes C, et.al. ¹⁰	59	Diabetes, hypertension	SS, TS, T	At onset	Non-severe	Survival
Garaci F, et.al. ¹¹	44	Recent acute hepatitis	VoG, StS, T, ICV	2 weeks	Severe	Not reported
HemAsian H, et.al. ¹²	65	None	SS; TS	At onset	Severe	Survival
Poillon G, et.al. ¹³	62	Morbid obesity	TS, StS, VoG, ICV	At onset	Severe	Not reported
	54	Remission breast cancer	TS	2 weeks	Severe	Not reported
Dahl-Cruz F, et.al. ¹⁴	53	Ex-smoker	SSS, TS	1 week	Severe	Survival
Klein D, et.al. ¹⁵	29	Iron deficiency anemia	TS, SS	1 week	Severe	Survival
Malentacci M, et.al. ¹⁶	81	Ocular myasthenia, prostate adenocarcinoma, CLL, hemolytic anemia	SS	3 weeks	Severe	Death
Chougar L, et.al. ¹⁷	72	None	ICV, VoG, BVoR	At onset	Severe	Death
Cavalcanti D, et.al. ¹⁸	38	Mild autism spectrum	SSS, TS, SS, T, StS	1 week	Severe	Death
	41	None	ICV, VoG, SS	2 weeks	Severe	Death
	31	None	VoG, ICV, ISS	1 week	Severe	Death
Baudar C, et.al. ¹⁹	33	Morbid obesity	CoVT	5 weeks	Non-severe	Death
Roy-Ghosh F, et.al. ²⁰	63	Not reported	SS, TS	2 weeks	Severe	Dath
Bolaji P, et.al. ²¹	63	Asthma, diabetes	Bilateral CoVT	1 week	Severe	Survival

TABLE 2: REPORTED CASES OF CEREBRAL VENOUS THROMBOSIS IN COVID-19 PATIENTS. SS, SIGMOID SINUS; TS, TRANSVERSE SINUS; T, TORCULA; VoG, VEIN OF GALLEN; STS, STRAIGHT SINUS; ICV, INTERNAL CEREBRAL VEIN; SSS, SUPERIOR SAGITAL SINUS; BVoR, BASAL VEIN OF SOSENTHAL; ISS, INFERIOR SAGITAL SINUS; CoVT, CORTICAL VEIN THROMBOSIS; CLL, CHRONIC LUMPHATIC LEUKEMIA.

Laboratory normal range	Laboratory findings
ANAs	Negative
ENAs	
<i>Ro</i> (Index <0.9)	0.3
<i>La</i> (Index <0.9)	0.0
<i>SM</i> (Index <0.9)	0.8
<i>RNP</i> (Index <0.9)	0.2
DNA antibodies (<1/10)	Negative
Complement C3 (80-193 mg/dl)	184.21
Complement C4 (14-57 mg/dl)	39.99
Lupus anticoagulant (Normalized ratio <1.5)	1.1
Anticardiolipin IgG antibodies (GPL U/ml <20)	2.1
Anticardiolipin IgM antibodies (GPL U/ml <10)	2.4
Protein C activity (70-140%)	101%
Protein S activity (60-150%)	96.9%
Antithrombin III activity (80-120%)	113%
Factor VIII activity (50-150%)	130%
Activated protein C resistance (<0.7)	0.75
β 2 microglobulin (0.2-8 mg/L)	1.2
Homocystein (12-15 μ mol/L)	13
Factor V Leiden mutation	Absent
Prothrombin gene mutation (G20210A)	Absent

TABLE 3: THROMBOPHILIA ANALYSIS.

In Conclusion, cerebral venous thrombosis is a potential complication of COVID-19, even in patients with non-severe course of the disease by a different mechanism than thromboinflammation. Microcirculatory dysfunction from viral endothelial interaction is an alternative mechanism in this case associated with different thrombotic diathesis, provoking unusual site thrombosis as the deep cerebral venous system.

DECLARATION OF CONFLICTS OF INTEREST

There is nothing to declare as competing interest for any of the authors including the corresponding author.

SOURCES OF FINANCING

This research has not received any specific grant from agencies in the public, commercial, or non-profit sectors.

REFERENCIAS

- [1] Gupta A, Madhavan MV, Sehgal K, Nair N, Mahajan S, Sehrawat TS, et al. Extrapulmonary manifestations of COVID-19. *Nat Med*. 2020;26(7):1017-32. doi: 10.1038/s41591-020-0968-3
- [2] Mao L, Jin H, Wang M, Hu Y, Chen S, He Q, et al. Neurologic Manifestations of Hospitalized Patients With Coronavirus Disease 2019 in Wuhan, China. *JAMA Neurol*. 2020; 77(6):683-690. doi: 10.1001/jamaneurol.2020.1127
- [3] Han H, Yang L, Liu R, Liu F, Wu KL, Li J, et al. Prominent changes in blood coagulation of patients with SARS-CoV-2 infection. *Clin Chem Lab Med*. 2020;58(7):1116-20. doi: 10.1515/cclm-2020-0188
- [4] Bhatia R, Srivastava MVP. COVID-19 and Stroke: Incidental, Triggered or Causative. *Ann Indian Acad Neurol*. 2020;23(3):318-24. doi: 10.4103/aian.AIAN38020
- [5] Connors JM, Levy JH. COVID-19 and its implications for thrombosis and anticoagulation. *Blood*. 2020;135(23):2033-40. doi: 10.1182/blood.2020006000
- [6] Al-Samkari H, Karp Leaf RS, Dzik WH, Carlson JC, Fogerty AE, Waheed A, et al. COVID and Coagulation: Bleeding and Thrombotic Manifestations of SARS-CoV2 Infection. *Blood*. 2020;135(23):2033-2040. doi: 10.1182/blood.2020006000
- [7] Shi W, Lv J, Lin L. Coagulopathy in COVID-19: Focus on vascular thrombotic events. *J Mol Cell Cardiol*. 2020;146:32-40. doi: 10.1016/j.yjmcc.2020.07.003
- [8] Li Y, Li M, Wang M, Zhou Y, Chang J, Xian Y, et al. Acute cerebrovascular disease following COVID-19: a single center, retrospective, observational study. *Stroke Vasc Neurol*. 2020;5(3):279-284. doi: 10.1136/svn-2020-000431
- [9] Sweid A, Hammoud B, Bekelis K, Missios S, Tjoumakaris SI, Gooch MR, et al. Cerebral ischemic and hemorrhagic complications of coronavirus disease 2019. *Int J Stroke*. 2020;15(7):733-742. doi: 10.1177/1747493020937189
- [10] Hughes C, Nichols T, Pike M, Subbe C, Elghenzai S. Cerebral Venous Sinus Thrombosis as a Presentation of COVID-19. *Eur J Case Rep Intern Med*. 2020;7(5):001691. doi: 10.12890/2020_001691
- [11] Garaci F, Di Giuliano F, Picchi E, Da Ros V, Floris R. Venous cerebral thrombosis in COVID-19 patient. *J Neurol Sci*. 2020;414:116871. doi: 10.1016/j.jns.2020.116871
- [12] Hemasian H, Ansari B. First case of Covid-19 presented with cerebral venous thrombosis: A rare and dreaded case. *Rev Neurol (Paris)*. 2020;176(6):521-523. doi: 10.1016/j.neurol.2020.04.013
- [13] Poillon G, Obadia M, Perrin M, Savatovsky J, Lecler A. Cerebral venous thrombosis associated with COVID-19 infection: Causality or coincidence? *J Neuroradiol*. 2020;S0150-9861(20)30167-X. doi: 10.1016/j.neurad.2020.05.003
- [14] Dahl-Cruz F, Guevara-Dalrymple N, López-Hernández N. [Cerebral venous thrombosis and SARS-CoV-2 infection]. *Rev Neurol*. 2020;70(10):391-392. doi: 10.33588/rn.7010.2020204
- [15] Klein DE, Libman R, Kirsch C, Arora R. Cerebral venous thrombosis: A typical presentation of COVID-19 in the young. *J Stroke Cerebrovasc Dis*. 2020;29(8):104989. doi: 10.1016/j.jstrokecerebrovasdis.2020.104989

- [16] Malentacchi M, Gned D, Angelino V, Demichelis S, Perboni A, Veltri A, et al. Concomitant brain arterial and venous thrombosis in a COVID-19 patient. *Eur J Neurol.* 2020; 10.1111/ene.14380. doi: 10.1111/ene.14380
- [17] Chougar L, Mathon B, Weiss N, Degos V, Shor N. Atypical Deep Cerebral Vein Thrombosis with Hemorrhagic Venous Infarction in a Patient Positive for COVID-19. *AJNR Am J Neuroradiol.* 2020;41(8):1377-79. doi: 10.3174/ajnr.A6642
- [18] Cavalcanti DD, Raz E, Shapiro M, Dehkharghani S, Yaghi S, Lillemoe K, et al. Cerebral Venous Thrombosis Associated with COVID-19. *AJNR Am J Neuroradiol.* 2020;41(8):1370-76. doi: 10.3174/ajnr.A6644
- [19] Baudar C, Duprez T, Kassab A, Miller N, Rutgers MP. COVID-19 as triggering co-factor for cortical cerebral venous thrombosis? *J Neuroradiol.* 2020;S0150-9861(20)30205-4. doi: 10.1016/j.neurad.2020.06.008
- [20] Roy-Gash F, De Mesmay M, Devys JM, Vespignani H, Blanc R, Engrand N. COVID-19-associated acute cerebral venous thrombosis: clinical, CT, MRI and EEG features. *Crit Care.* 2020;24(1):419. doi: 10.1186/s13054-020-03131-x
- [21] Bolaji P, Kukoyi B, Ahmad N, Wharton C. Extensive cerebral venous sinus thrombosis: a potential complication in a patient with COVID-19 disease. *BMJ Case Rep.* 2020;13(8):e236820. doi: 10.1136/bcr-2020-236820
- [22] Saposnik G, Barinagarrementeria F, Brown RD, Bushnell CD, Cucchiara B, Cushman M, et al. Diagnosis and management of cerebral venous thrombosis: a statement for healthcare professionals from the American Heart Association/American Stroke Association. *Stroke.* 2011;42(4):1158-92. doi: 10.1161/STR.0b013e31820a8364
- [23] Abou-Ismaïl MY, Diamond A, Kapoor S, Arafah Y, Nayak L. The hypercoagulable state in COVID-19: Incidence, pathophysiology, and management. *Thrombosis Research.* 2020;194:101-115. doi: 10.1016/j.thromres.2020.06.029
- [24] Atallah B, Mallah SI, AlMahmeed W. Anticoagulation in COVID-19. *Eur Heart J Cardiovasc Pharmacother.* 2020;6(4):260-261. doi: 10.1093/ehjcvp/pvaa036
- [25] Mummery RS, Rider CC. Characterization of the heparin-binding properties of IL-6. *J Immunol.* 2000 ;165(10):5671-9. doi: 10.4049/jimmunol.165.10.5671